

 **onemytis**[®]

— with —
airplasma[®]
technology

HISTOLOGICAL AND MORPHOMETRIC
ANALYSIS OF THERMAL SHOCK
ALTERATIONS IN TISSUE SAMPLES
OBTAINED WITH THE DEVICE FOR PLASMA
SURGERY NAMED
ONEMYTIS[®]



Vet Clinic
Roma Sud
Roma

histological examinations reports:

UNIVERSITÀ DEGLI STUDI DI TORINO
Struttura Didattica Speciale Veterinaria
Grugliasco



Vet Clinic
Roma Sud s.r.l.

P.Iva 06622531009

via Pilade Mazza n. 24 - 00173 Roma
tel. +39 06 72 36 171
fax +39 06 72 63 19 57

www.veterinariaromasud.it



produced by

OTECH
INDUSTRY

Otech Industry s.r.l.

Uia Chambery 79/12 - 10142 Torino (TO)
tel. +39 011 78 08 188
fax +39 011 04 41 221

P.IVA 02390580062
info@otechindustry.it

www.otechindustry.it

histological examinations reports:

Università Degli Studi di Torino
Struttura Didattica Speciale Veterinaria
Ospedale Veterinario Universitario

Largo Paolo Braccini 2-5 - 10095 Grugliasco (TO)
tel. +39 011 67 09 157
fax +39 011 67 09 165

DESCRIPTION OF THE DEVICE IN EQUIPMENT USED FOR OBTAINING THE SAMPLES

Onemytis® Device for plasma surgery

Airplasma® technology

The Airplasma® technology is the elimination of the insulating power, which through an electronic process is transformed into an ideal energy conductor. With this technology it is possible to operate at a low temperature, which reaches a maximum of 50° C and which allows both to achieve vaporization of the tissue to be removed and hemostasis of the vessels. There is no need of any external source of inert gas (*Argon* or *Helium*) or of return plates, and therefore it helps preventing the propagation of current and the generation of heat in the patient's body.

The technology used by this device allows to carry out operations of cutting, ablation and coagulation of small vessels without varying the working tool.



Onemytis® device with Airplasma® technology

Case 1

Soft palate sample of 0.8 cm size

Description

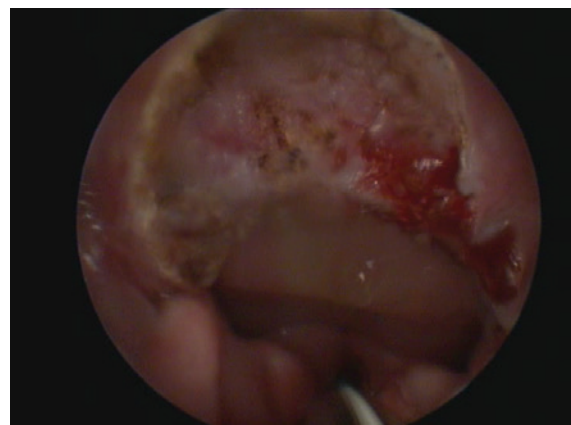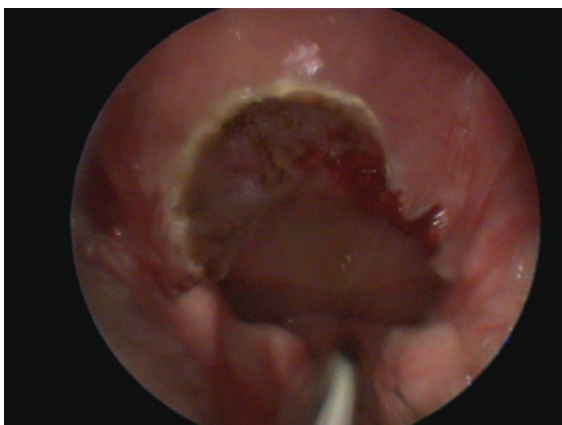
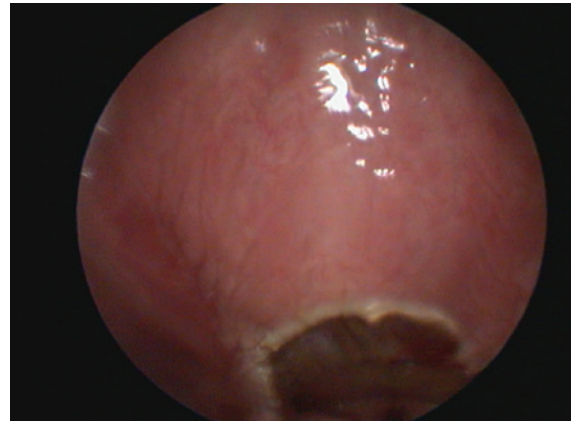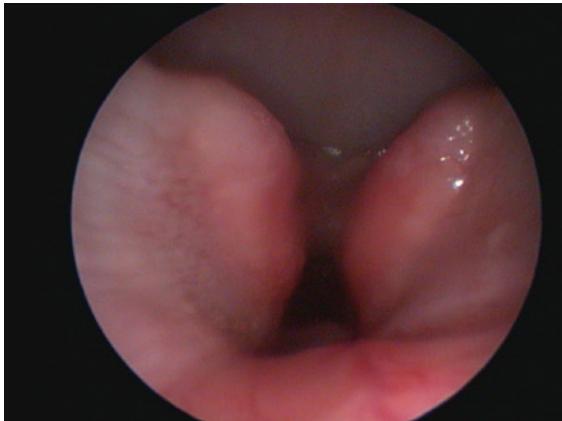
Evaluation of the larynx in patient hospitalized for respiratory crisis. Impressive macroglossia, elongated soft palate that imprisons the epiglottis. Arytenoids medialized with mucosal edema and eversion of the laryngeal sacs.

Comment

Brachicephalic syndrome with laryngeal collapse of grade II. It has been also done the stapiloplasty with surgical plasma device Onemytis[®].

Surgeon

Dr. Paolo Cortelli Panini.



Larynx treated with Onemytis[®]

Università Degli Studi di Torino
Struttura Didattica Speciale Veterinaria
Ospedale Veterinario Universitario
Cod. Fisc. 80088230018 P.IVA: 02099550010
Largo Paolo Braccini 2-5 - 10095 GRUGLIASCO (TO)
Telefono (+39)011 6709157 o (+39)011 6709158, fax (+39)011 6709165
Direttore della SDSV : Prof. Domenico Bergero
Direttore Sanitario: Dott.ssa Emanuela Morello



Customer: **CLINICA VETERINARIA ROMA SUD S.R.L.**
Address: VIA PILADE MAZZA 24 00173 ROMA 00173

Tel:
CF:

Patient: [REDACTED] (**ZEUS**)

Case: [REDACTED]

Micr/Tat:

Species: DOG

Breed: FRENCH
BULLDOG

Gender: MALE

HISTOLOGICAL EXAMINATION REPORT

Creation date: 17/07/2015 , Compiled by: Dr. Iussich Selina

Description	Values
Protocol nr°	B599/15
Biopsy of	soft palate
Upon request of Dr.	Panini

It has highlighted the following things:

Macroscopic finding

sample of 0,8 cm size

Histological findings

Examined the sections of oral mucosa, submucosa and salivary glands in the absence of significant lesions. It has been detected heat damage in the tissue area of surgical excision for about 300 microns. The epithelium, however, appears damaged also in portions at a greater distance (about 500 microns).

Findings consistent with the diagnosis of:

absence of significant lesions (thermal damage assessment).

Il responsabile
Dr. Iussich Selina

Case 2

Soft palate sample of 0.5 cm size

Description

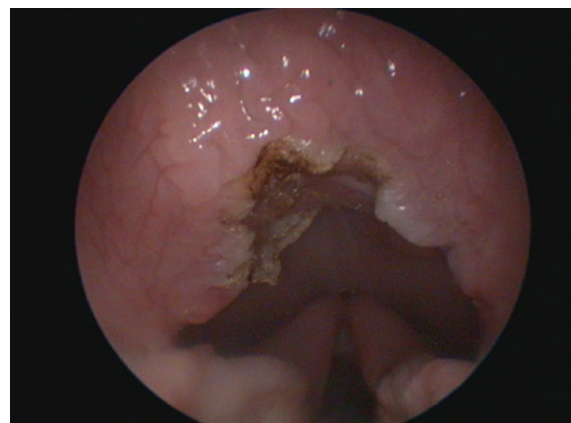
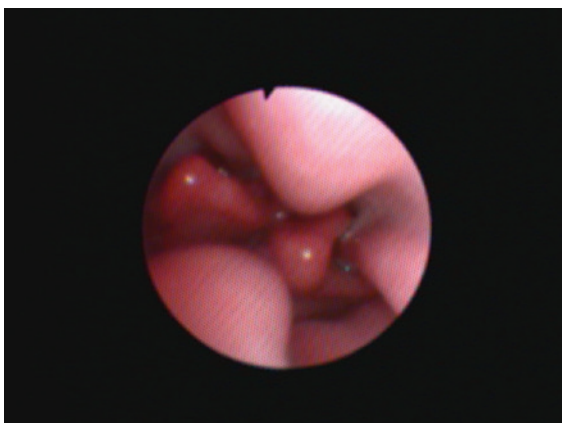
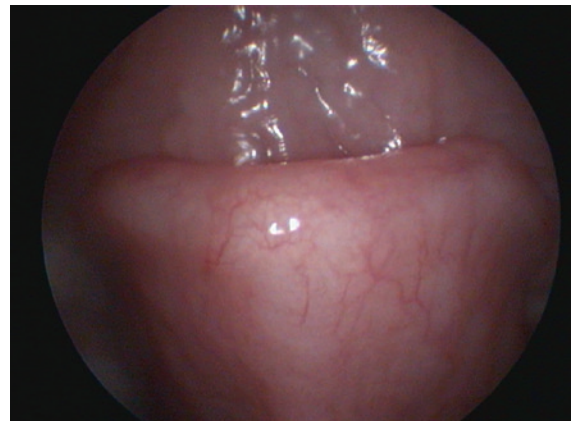
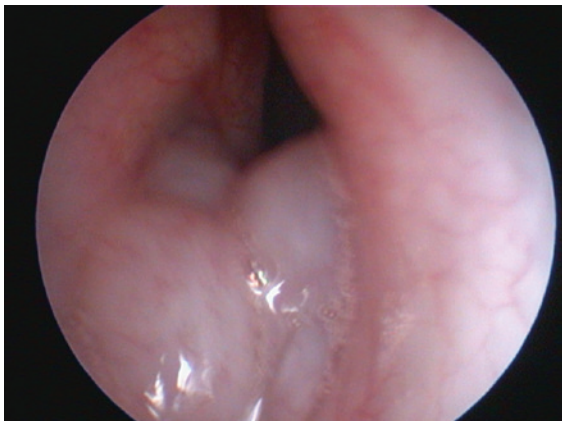
Typical mouth of brachycephalic. Macroglossia, exuberant soft palate that imprisons itself into the epiglottis. Altered larynx with normochromic and hypershining mucosa, medialization of arytenoids with contact during exhalation. Eversion of the laryngeal sacs. Trachea with normochromic and normoreflactant mucosa, visible submucous vessels, bronchi of the left and right compartment within normal limits. Left front nose within normal limits, right front presence of aberrant basins. Rear nose without aberrant basins, mild mucosal hypercromia nasopharyngeal with possible alteration of nalt.

Comment

Endoscopic framework compatible with the brachycephalic syndrome, exuberant soft palate, laryngeal collapse of II/III degree. It has been performed rhinoplasty and staphyloplastic.

Surgeon

Dr. Paolo Cortelli Panini.



Larynx treated with Onemytis[®]

Università Degli Studi di Torino
Struttura Didattica Speciale Veterinaria
Ospedale Veterinario Universitario
Cod. Fisc. 80088230018 P.IVA: 02099550010
Largo Paolo Braccini 2-5 - 10095 GRUGLIASCO (TO)
Telefono (+39)011 6709157 o (+39)011 6709158, fax (+39)011 6709165
Direttore della SDSV : Prof. Domenico Bergero
Direttore Sanitario: Dott.ssa Emanuela Morello



Customer: **CLINICA VETERINARIA ROMA SUD S.R.L.**
Address: VIA PILADE MAZZA 24 00173 ROMA 00173

Tel:
CF:

Patient: [REDACTED] (BRUNO)

Case: [REDACTED]

Micr/Tat:

Species: DOG

Breed: FRENCH
BULLDOG

Gender: MALE

Date of birth: 2/7/2013

HISTOLOGICAL EXAMINATION REPORT

Creation date: 08/07/2015 , Compiled by: Dr. Iussich Selina

Description	Values
Protocol nr°	B580/15
Biopsy of	soft palate
Upon request of Dr.	Panini

It has highlighted the following things:

Macroscopic finding

sample of 0.5 cm size

Histological findings

Examined histological sections of fibrous and glandular tissue covered by epithelium, in the absence of significant lesions. It has been detected heat iatrogenic damage with epithelial detachment and degeneration of collagen, which extends along the entire cutting surface and affects the tissue for about 250 microns in depth.

Findings consistent with the diagnosis of:

absence of significant lesions

Il responsabile
Dr. Iussich Selina

Case 3

Soft palate sample of 0.5 cm size

Description

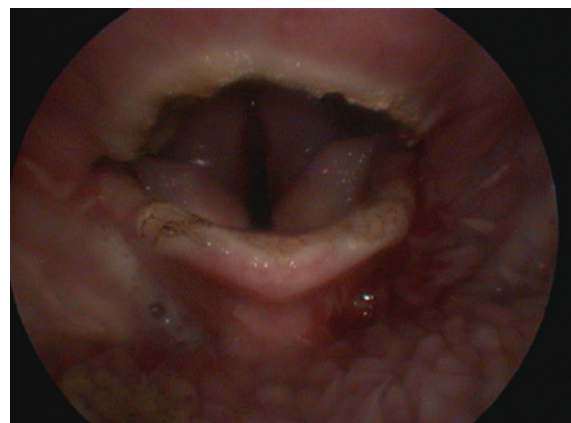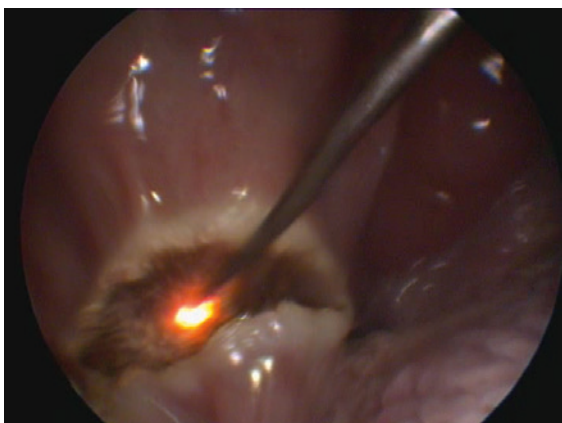
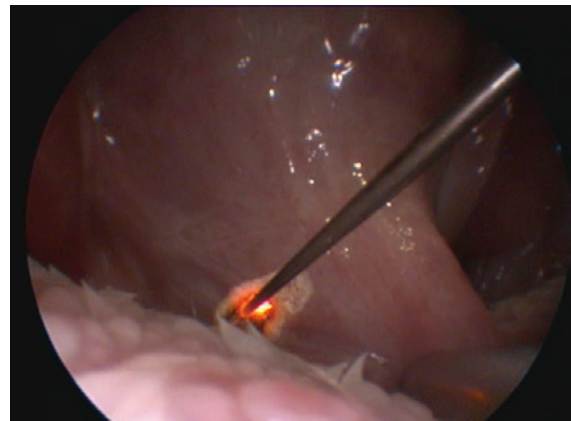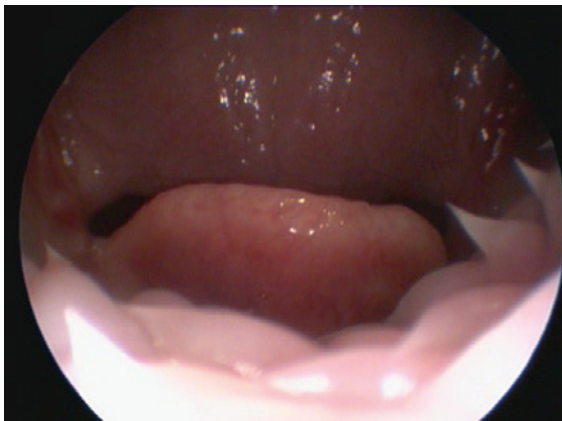
Patient with slight macropalasia, exuberant soft palate, larynx within normal limits. Nasopharynx altered by the presence of aberrant caudal basins and irregular mucosa in dorsal surface (suspected nasopharyngitis linfoplasmaticity).

Comment

Endoscopic framework compatible with the soft palate elongation. It has been done staphyloplastic and biopsies of nasopharyngeal mucosa.

Surgeon

Dr. Paolo Cortelli Panini.



Larynx treated with Onemytis[®]

Università Degli Studi di Torino
Struttura Didattica Speciale Veterinaria
Ospedale Veterinario Universitario
Cod. Fisc. 80088230018 P.IVA: 02099550010
Largo Paolo Braccini 2-5 - 10095 GRUGLIASCO (TO)
Telefono (+39)011 6709157 o (+39)011 6709158, fax (+39)011 6709165
Direttore della SDSV : Prof. Domenico Bergero
Direttore Sanitario: Dott.ssa Emanuela Morello



Customer: **CLINICA VETERINARIA ROMA SUD S.R.L.**
Address: VIA PILADE MAZZA 24 00173 ROMA 00173

Tel:
CF:

Patient: [REDACTED] (NINA)

Case: [REDACTED]

Micr/Tat:

Species: DOG

Breed: FRENCH
BULLDOG

Gender: FEMALE

Date of birth: 23/5/2014

HISTOLOGICAL EXAMINATION REPORT

Creation date: 03/07/2015 , Compiled by: Dr. Iussich Selina

Description	Values
Protocol nr°	B550/15
Biopsy of	soft palate
Upon request of Dr.	Panini

It has highlighted the following things:

Macroscopic finding

sample of 0.5 cm size not fixed

Histological findings

It has been examined the fibroadipose and glandular tissue sections severely autolytic.
There is evident presence, along the proximal edge of the sample, of instrumental burn mark that extends longitudinally along the sample for a stretch of about 280 microns.
Glandular structures and the epithelium are not significantly altered.

Findings consistent with the diagnosis of:

Severe autolysis, the absence of significant lesions.

Il responsabile
Dr. Iussich Selina

Case 4

Sample of soft palate of 1 x 0.7 cm size

Description

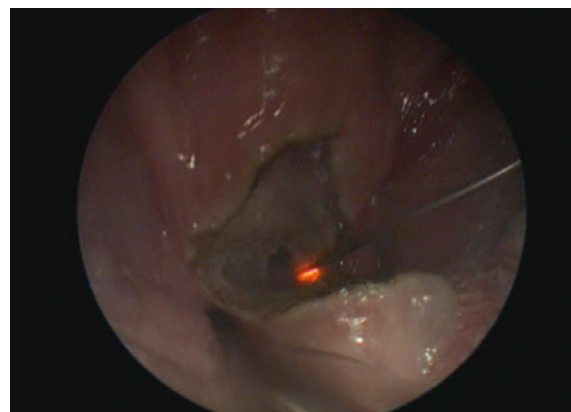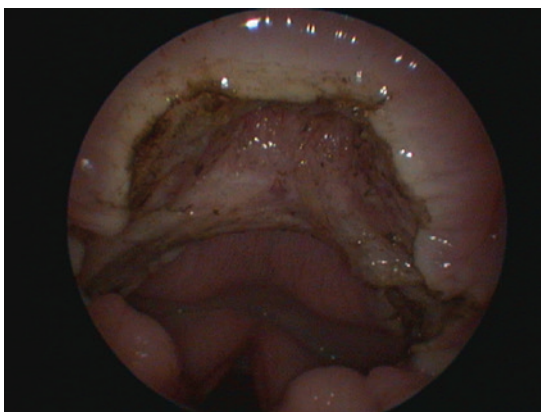
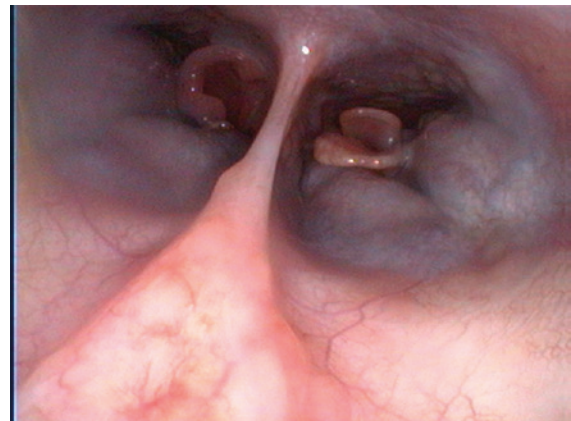
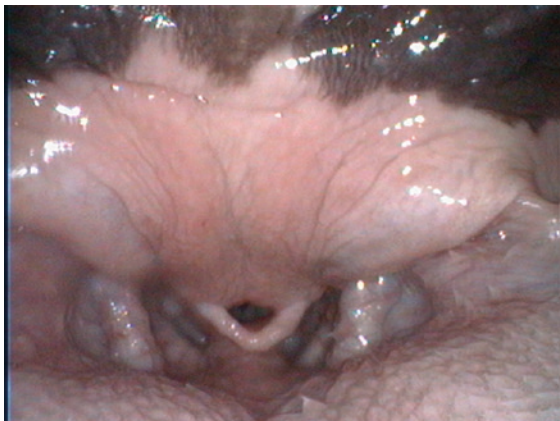
Patient with marked macroglossia. Soft exuberant palate that imprisons itself in the epiglottis. Medialization of arytenoids who present with slight mucosal edema. Marked eversion of the laryngeal sacs blocking the laryngeal rise.

Comment

Endoscopic framework compatible with the brachycephalic syndrome. Laryngeal collapse of II degree. It has been done staphyloplastic and treatment of vesicles with the Onemytis[®] plasma device.

Surgeon

Dr. Paolo Cortelli Panini.



Oral cavity treated with Onemytis[®]

Università Degli Studi di Torino
Struttura Didattica Speciale Veterinaria
Ospedale Veterinario Universitario
Cod. Fisc. 80088230018 P.IVA: 02099550010
Largo Paolo Braccini 2-5 - 10095 GRUGLIASCO (TO)
Telefono (+39)011 6709157 o (+39)011 6709158, fax (+39)011 6709165
Direttore della SDSV : Prof. Domenico Bergero
Direttore Sanitario: Dott.ssa Emanuela Morello



Customer: **CLINICA VETERINARIA ROMA SUD S.R.L.**
Address: VIA PILADE MAZZA 24 00173 ROMA 00173

Tel:
CF:

Patient: ██████████ (**DODY**)

Case: ██████████

Micr/Tat:

Species: DOG

Breed: FRENCH
BULLDOG

Gender: MALE

Date of birth: 2/7/2013

HISTOLOGICAL EXAMINATION REPORT

Creation date: 08/07/2015 , Compiled by: Dr. Iussich Selina

Description	Values
Protocol nr°	B577/15
Biopsy of	soft palate
Upon request of Dr.	Panini

It has highlighted the following things:

Macroscopic finding
Sample of 1 x 0.7 cm size
Histological findings
Examined histological sections of fibrous and glandular tissue covered by stratified and coneified epithelium, in the absence of significant lesions . It detects heat iatrogenic damage with epithelial detachment and degeneration of collagen, which extends along the entire cutting surface and affects the tissue for about 200 microns in depth.
Findings consistent with the diagnosis of:
absence of significant lesions

Il responsabile
Dr. Iussich Selina

Case 5

Sample of cutaneous neoformation of 0,3 cm size

Surgeon

Dr. Daniela Mignacca.

Università Degli Studi di Torino
 Struttura Didattica Speciale Veterinaria
 Ospedale Veterinario Universitario
 Cod. Fisc. 80088230018 P.IVA: 02099550010
 Largo Paolo Braccini 2-5 - 10095 GRUGLIASCO (TO)
 Telefono (+39)011 6709157 o (+39)011 6709158, fax (+39)011 6709165
 Direttore della SDSV : Prof. Domenico Bergero
 Direttore Sanitario: Dott.ssa Emanuela Morello



Customer: **CLINICA VETERINARIA ROMA SUD S.R.L.**
 Address: VIA PILADE MAZZA 24 00173 ROMA 00173

Tel:
 CF:

Patient: [REDACTED] (**PRINCIPESSA**) Case: [REDACTED] Micr/Tat:
 Species: DOG Breed: COCKER Gender: FEMALE STER. Date of birth: 29/7/2006
 ESPANIEL

HISTOLOGICAL EXAMINATION REPORT

Creation date: 04/08/2015 , Compiled by: Dr. Iussich Selina

Examination date : 28/07/2015

Description	Values
Protocol nr°	B653/15
Biopsy of	cutaneous neoformation
Upon request of Dr.	Mignacca

It has highlighted the following things:

Macroscopic finding
Skin 2x1x0,5 cm with neoformation of 0.3 cm size
Histological findings
Examined histological sections of the skin and subcutaneous tissue characterized by dermal tumor, not well encapsulated, but well-defined consisted of well differentiated melanocytes arranged in solid structure; the cells appear normotypical, with cytoplasm containing brownish granules and nuclei not always visible characterized by compact chromatin and rare obvious nucleoli; there are visible rare mitosis.
There are visible areas of thermal stress in marginal level involving the sample for approximately 500 microns but not affecting the reading of the preparation and not involving the nodule in question.
Examination of the surgical edges
ABSENCE OF INFILTRATION IN THE EXAMINED SECTION
Findings consistent with the diagnosis of:
melanocytoma (pigmented nevus)

Il responsabile
 Dr. Iussich Selina

Case 6

Gingival neof ormation sample of 1 cm size

Surgeon

Dr. Daniela Mignacca.

Università Degli Studi di Torino
 Struttura Didattica Speciale Veterinaria
 Ospedale Veterinario Universitario
 Cod. Fisc. 80088230018 P.IVA: 02099550010
 Largo Paolo Braccini 2-5 - 10095 GRUGLIASCO (TO)
 Telefono (+39)011 6709157 o (+39)011 6709158, fax (+39)011 6709165
 Direttore della SDSV : Prof. Domenico Bergero
 Direttore Sanitario: Dott.ssa Emanuela Morello



Customer: **CLINICA VETERINARIA ROMA SUD S.R.L.**
 Address: VIA PILADE MAZZA 24 00173 ROMA 00173

Tel:
 CF:

Patient: [REDACTED] (MAX) Case: [REDACTED] Micr/Tat:
 Species: DOG Breed: BOXER Gender: MALE Date of birth: 29/7/2008

HISTOLOGICAL EXAMINATION REPORT

Creation date: 04/08/2015 , Compiled by: Dr. Iussich Selina

Examination date : 28/07/2015

Description	Values
Protocol nr°	B651/15
Biopsy of	gingival neof ormation
Upon request of Dr.	Mignacca

It has highlighted the following things:

<p>Macroscopic finding</p> <p>2 samples of 1 cm size</p>
<p>Histological findings</p> <p>Both tested samples are characterized by epithelial neoplastic lesion focally infiltrating constituted by Enamel cells arranged in cords that go into the submucosal surface. The neoplastic cells appear moderately atypical (anisocytosis and minor anisokaryosis) with moderate cytoplasm and vesicular nuclei with evident rare nucleoli and mitosis are not visible in the examined sections. Chronic inflammation is multifocally visible at the minimum level of submucosa.</p>
<p>Findings consistent with the diagnosis of:</p> <p>epulis acantomatosa (Low grade)</p>

Il responsabile
 Dr. Iussich Selina

Conclusions

Comment of the Onemytis® Plasma surgery device's performances

Histological examinations performed with Onemytis® device showed moderate necrosis, slightly higher than its total absence achievable with cold blade. The thermal damage on the tissues interesting a 200 to 500 micron surface, and then the lesions are never significant.

The Onemytis® device has proven to be an effective and safe tool due to low tissue temperature dissipation. In addition it has allowed to obtain net cutting surfaces with good control of bleeding.

The Onemytis® device allowed a marked reduction in operating times without any impairment of operational quality.

Paolo Cortelli Panini

